

# PERIPHERAL LESIONS DETECTED BY OPTOMAP ASSOCIATED WITH NEARLY 5 FOLD RISK OF PROGRESSION IN DISEASE

**The presence of predominantly peripheral lesions was associated with an almost 5 fold risk in the progression of diabetic retinopathy (DR) over 4 years<sup>1</sup>.**

**A study published in Ophthalmology finds 50% of diabetic lesions located outside the area of ETDRS Gold Standard area<sup>2</sup>. These lesions might result in a more severe grade of retinopathy in 13% of eyes.**

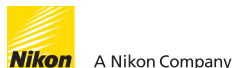The results of several clinical studies comparing **optomap**<sup>®</sup> ultra-widefield (UWF<sup>™</sup>) images have indicated that there is substantial agreement with Early Treatment Diabetic Retinopathy Study (ETDRS) 7-standard (ETDRS) film photographs and dilated fundus examination in determining diabetic retinopathy severity<sup>1,2,3,4</sup>. The peripheral lesions identified using UWF in this cohort suggested a more severe assessment of diabetic retinopathy in 13% of eyes than was suggested by the lesions within the ETDRS fields. The presence of predominantly peripheral lesions was associated with the progression of diabetic retinopathy (DR) over 4 years, independent of baseline severity and HbA1c<sup>1</sup>.

*“The presence of DR lesions located predominantly in this peripheral area seemed to identify a subset of eyes at greatly increased risk of DR progression and onset of PDR...the rigorous evaluation of the peripheral retina may become an essential and routine component of accurately characterizing DR severity, and thus may prompt a revision of the ETDRS grading algorithms to best optimize the association of DR severity grade and clinical outcome<sup>1</sup>.”*

*Ophthalmology, 2015*

See how **optomap** will help you manage your diabetic patients.

For more information call **800-854-3039** or email **BDS@optos.com**



1. Peripheral Lesions Identified on Ultrawide Field Imaging Predict Increased Risk of Diabetic Retinopathy Progression over 4 Years. Ophthalmology 2015.  
2. Hemorrhage and/or Microaneurysm Severity and Count in Ultrawide Field Images and Early Treatment Diabetic Retinopathy Study Photography. Ophthalmology. 2017.  
3. Nonmydriatic Ultrawide Field Retinal Imaging Compared with Dilated Standard 7-Field 35mm Photography and Retinal Specialist Examination for Evaluation of Diabetic Retinopathy. American Journal of Ophthalmology. 2012  
4. Peripheral Lesions Identified by Mydriatic Ultrawide Field Imaging: Distribution and Potential Impact on Diabetic Retinopathy Severity. Ophthalmology. 2013

# CLINICAL SUMMARY

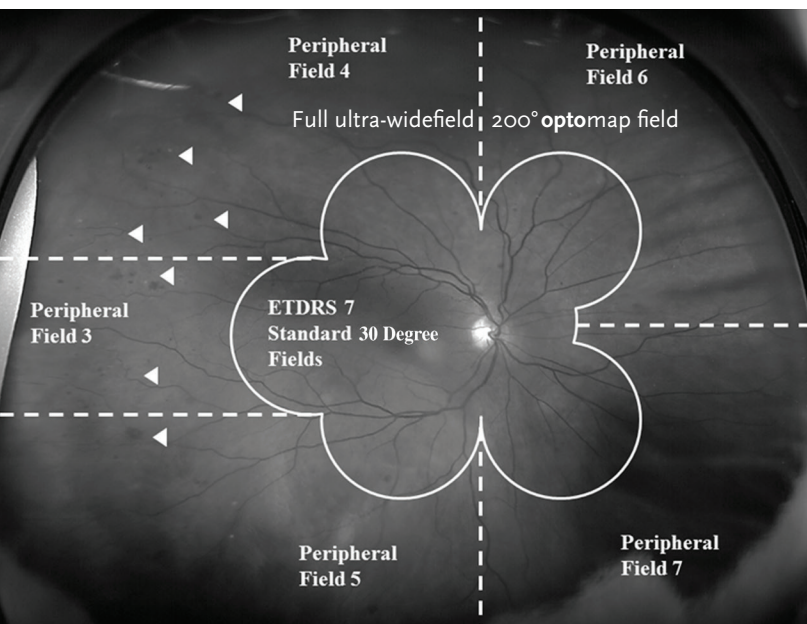
## Peripheral Lesions Identified on Ultrawide Field Imaging Predict Increased Risk of Diabetic Retinopathy Progression over 4 Years.

Silva, Cavallerano, Haddad, Kwak, Dyer, Omar, Shikari, Aiello, Sun, Aiello  
Ophthalmology - 2015

The results of several clinical studies<sup>1,2,3,4</sup> validate that **optomap** images had substantial agreement with the gold standard Early Treatment Diabetic Retinopathy Study (ETDRS) film for the diagnosis and severity grading of diabetic retinopathy.

In addition, the latest study identified that 50% of the lesions were in the area outside of ETDRS and that in 13% of patients these lesions suggested a more severe grade of retinopathy<sup>2</sup>.

The presence of predominantly peripheral lesions was associated with the progression of diabetic retinopathy (DR) over 4 years, independent of baseline severity and HbA1c.



Comparison field of view between **optomap** and the area covered by a standard ETDRS montage.

- Eyes with predominantly peripheral lesions (defined as outside of ETDRS 7 standard field) had a 4.7 fold increased risk of progression to proliferative diabetic retinopathy (PDR).
- Eyes with predominantly peripheral lesions had a 3.2 fold risk of 2 step progression in DR.
- For every 10 hemorrhages and microaneurysms identified on **optomap**, the risk of DR progression over 4 years may be increased 24%<sup>4</sup>.
- There are ongoing longitudinal studies in this cohort to determine the clinical significance of these peripheral lesions.
- The 2015 study suggests “Given that evaluation of these peripheral lesions may substantially alter risks of DR progression and onset of PDR, revision of the current ETDRS standard grading system may become necessary.”
- The patented UWF scanning laser technology from Optos provides a photograph of the fundus that supports the detection, diagnosis, analysis, documentation and management of ocular pathology and systemic disease, especially those that first present in the periphery.